

## Optical Measurements for the Detection of Colorectal Cancer – Does the Field Effect Exist?

Vadim Backman, Ph.D.  
Biomedical Engineering Department  
Northwestern University

---

---

---

---

---

---

---

---

## Colorectal Cancer (CRC)

- #2 killer of all cancers, 155K cases annually and 57K deaths – stagnant for 20 years
- 90%+ survival rate if caught early but today the majority (61%) are later stage
- Colonoscopy detects and removes a precursor to colon cancer, adenomatous polyp, thus decreasing future occurrence of CRC by 75-90%

---

---

---

---

---

---

---

---

## Why Colon Cancer Screening Program Does Not Work?

### Problem:

- Current guidelines: everybody over age 50 is recommended to undergo colonoscopy at least once every 10 years.
- There are >90 million Americans over age 50.
- 70-80% of colonoscopies are negative and unnecessary
- Colonoscopic screening of this entire eligible population is impossible due to
  - expense (annual cost would be ~\$50 billion)
  - insufficient number of endoscopists
  - patient reluctance (hate prep!)
  - complication rate.
- 85% of the population receives no colonoscopic CRC screening.

**Solution:** Develop a minimally invasive technology to identify patients who are at risk for CRC and would benefit from colonoscopy.

**Precedent:** Cervical cancer screening with Pap smear in the last 50 years reduced mortality from #1 cancer in women to #13!

---

---

---

---

---

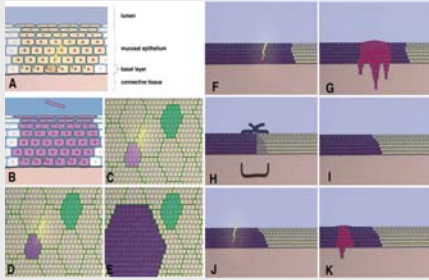
---

---

---



### Example I: Model of Head and Neck Squamous Cell Carcinoma: Primary Carcinomas and Second Field Tumor



Brakhuus, B. J.M. et al. Oncologist 2005;10:493-500

---

---

---

---

---

---

---

---

---

---

---

---

### Example I: Aero-digestive Cancers Condemned Mucosa: Clinical Consequences

- In up to 20% of head and neck cancers, the aerodigestive tract mucosa shows widespread precancerous lesions and additional tumors within 5 years.
- All occurrences of head & neck cancer had p53 mutations in normal mucosa
  - van Oijen et al, Cancer 2000
- Clinically, patients with one aerodigestive cancer it is mandatory that other organs be screened.
  - Brennan et al., NEJM 1995

---

---

---

---

---

---

---

---

---

---

---

---

### Example II: Field Effect in Lung Cancer

- Genetic/Epigenetic (methylation) events detectable in the lung tumor are also frequently noted in the adjacent histologically normal epithelium
- Second primaries (contralateral lung) common in patients with lung cancer
- Increased incidence of head and neck cancer in patients with lung cancer
  - Johnson et al., B. J. Natl. Cancer Inst., 1998
- Genetic changes in the histologically normal large-airway epithelial cells obtained at bronchoscopy.
  - Guo, M. et al. Clin. Cancer Res. 2004.
- Spectral karyotyping shows diffuse bronchial abnormalities in histologically normal mucosa
  - Varcella-Garcia et al., Am J Respir Crit Care Med. 2007

---

---

---

---

---

---

---

---


---

---

---

---

### Example II: Microarray from Microscopically Normal Right Mainstem Bronchus Predicts Lung Cancer



Spira et al., Nat Med. 2007 Mar;13(3):361-6.

---

---

---

---

---

---

---

---

---

---

### Example III: Commonly Used Biomarkers of “Field Effect” in CRC

- Focal Neoplastic Lesions to predict Proximal Neoplasia
  - adenoma on flex sigmoidoscopy Lewis et al. (Arch Intern Med. 2004 1881-7).
  - Rectal aberrant crypt foci (Takayama et al N Engl J Med. 1998; 339:1277.)
- Diffuse Alterations in the Histologically Normal Mucosa
  - Decreased apoptosis (Bernstein et al. Cancer Res. 1999 59:2353-7)
  - Increased proliferation (Ponz de Leon, et al Cancer Res. 1988 ;48:4121).

---

---

---

---

---

---

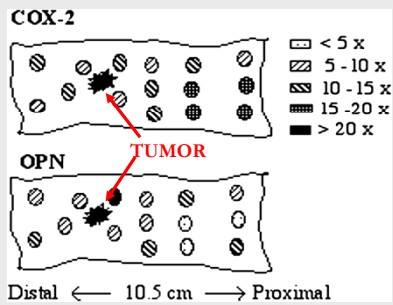
---

---

---

---

### CRC Field Carcinogenesis in Histologically Normal Mucosa: Microarray Evidence



Chen et al. Cancer Res 2004

---

---

---

---

---

---

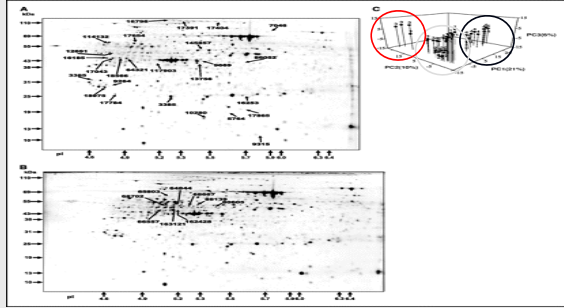
---

---

---

---

### CRC Field Carcinogenesis in Histologically Normal Mucosa: Proteomic Evidence



Polley et al. Cancer Res 2006 66: 6553-6562

---

---

---

---

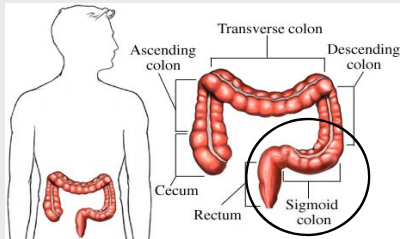
---

---

---

---

### CRC Field Effect and Its Implications for Screening: Flexible Sigmoidoscopy



---

---

---

---

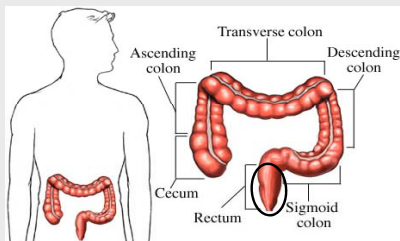
---

---

---

---

### CRC Field Effect and Its Implications for Screening: Can Tissue Optics Detect the Field Effect?



---

---

---

---

---

---

---

---

## Biophotonics and the Field Effect

- Previous efforts in biophotonics focused on detecting dysplasia, i.e. histologically defined changes in tissue.
- Our approach: sensing changes in tissue that CANNOT be detected by histopathology.
  - Spatially outside the extend of a histologically-defined neoplastic lesion.

---

---

---

---

---

---

---

---

## Optically-detectable Markers of the Field Effect

- Increased microvascular blood supply ← Polarization-gated spectroscopy
- Alterations of tissue microarchitecture ← Low-coherence enhanced backscattering (LEBS)
- Others???

---

---

---

---

---

---

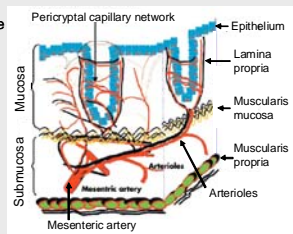
---

---

## Need For Depth Selectivity: Microvasculature

Field effect changes are most likely to be present in the mucosa

- In patients harboring colonic neoplasia, mucosa hyperproliferative and therefore hypermetabolic
- This would imply needs increased blood supply
- Pericyptal capillary plexus serves as the source for these epithelial cells
- However, these superficial capillaries comprise < 5% of blood supply—
- Therefore, to see an effect, these capillaries (within 100 microns from tissue surface) need to be selectively probed



- Depth-selective measurements can be achieved by polarization gating
- Penetration depth of differential polarization signal is  $\sim 2l_s \sim 100$   $\mu$ m

---

---

---

---

---


---

---

---

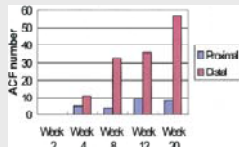
## Example I: Early Increase in Blood Supply (EIBS) as a Markers of Field Effect

### AOM-treated Rat Model of Colon Carcinogenesis



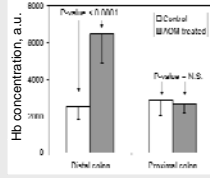
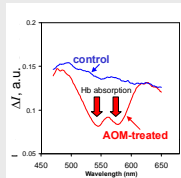
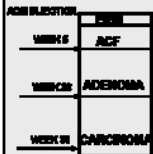• AOM (azoxymethane) treated rat – one of the most robust and widely used animal models of CRC.

• Replicates the morphological, cellular and genetic characteristics of human colon carcinogenesis.



Clin. Cancer Res., 2006

## Observation of EIBS in AOM-treated Rat Model of CRC

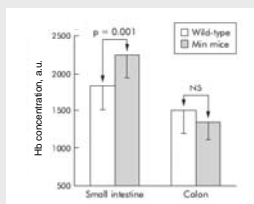


• EIBS precedes development of ACF and adenomas

• EIBS is diffusely present in >90% of tissue throughout the mucosa

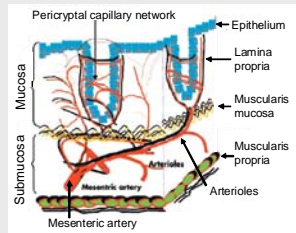
Gut, 54, 654-660 (2005)

## Validation of EIBS in the MIN Mouse



Gut, 54, 654-660 (2005)

## EIBS is Primarily a Limited to Mucosal Pericryptal Microvasculature




---

---

---

---

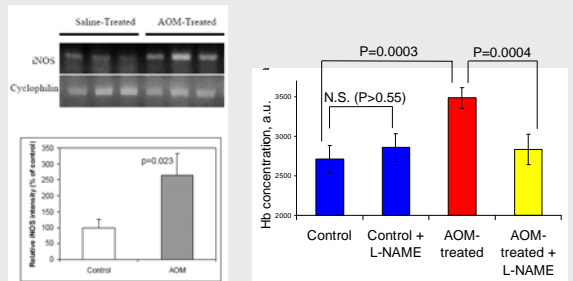
---

---

---

---

## Potential Mechanism of EIBS: iNOS Upregulation



FEBS, 581, 3857-3862 (2007)

---

---

---

---

---


---

---

---

## EIBS: In Vivo Clinical Validation

- 220 average risk screening patients
  - 51 with adenomas: 30 non-advanced adenomas, 9 multiple non-advanced adenomas, 12 advanced
  - 169 patients with no neoplasia including 26 with hyperplastic polyps




---

---

---

---

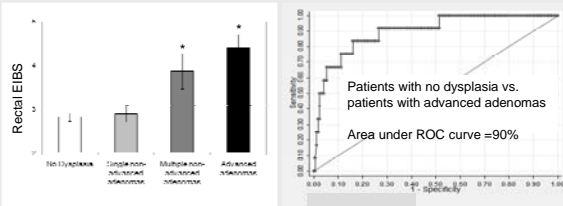
---

---

---

---

## Rectal EIBS is Indicative of Presence of Adenomas Throughout the Colon



EIBS reading: rectum only  
Adenoma location: throughout the colon

---

---

---

---

---

---

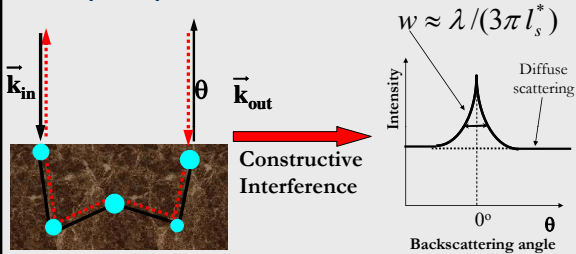
---

---

---

---

## Example II: Enhanced Backscattering (EBS): Self-interference Effect



Comparison with OCT:  
Both sample and reference arms are inside the sample!

---

---

---

---

---

---

---

---

---

---

## EBS has been notoriously difficult to study in biological tissue

### 1. Narrow EBS peaks

- In nonbiological media studied with EBS  $l_s^* \sim 10 \mu\text{m}$  and EBS FWHM  $\sim 0.1^\circ$ .
- In biological tissue  $l_s^* \sim 1000 \mu\text{m}$  and EBS is extremely narrow with FWHM  $\sim 0.001^\circ$ .

$$w \approx \lambda / (3\pi l_s^*)$$

### 2. Speckle

- Requires 1000x ensemble averaging

### 3. Single wavelength – lack of spectroscopic information

- Highly coherent laser light sources

### 4. Unclear benefits

- $l_s^*$  can be measured in tissue by other, simpler methods

---

---

---

---

---

---

---

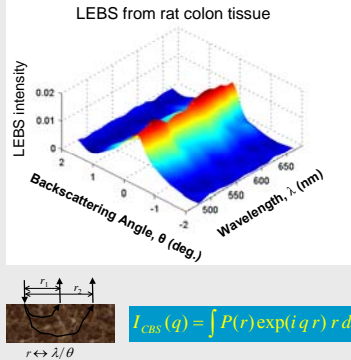
---

---

---

## Low-coherence EBS Spectroscopy

- LEBS: low-coherence illumination (Lsc-ils) and spectrally-resolved low-temporal coherence detection
- Broad EBS peak (FWHM - 0.5°)
- Speckle-free
- Spectroscopic information
- An LEBS peak contains information about a range of tissue depths within the upper limit determined by the spatial coherence length



Optics Letters, 29, 1906-1908 (2004)

---

---

---

---

---

---


---

---

---

---

## Need for Depth-selective Measurement: Colonic Crypt



- Colonic crypt heterogeneous with multiple different compartments
- Base of the crypt (stem cells) believed to be the earliest target during colon carcinogenesis
- LEBS allows depth selective mucosal interrogation

---

---

---

---

---

---

---

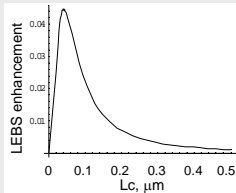
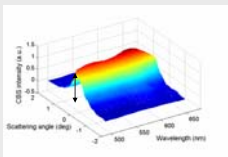
---

---

---

## LEBS Provides Unique Information about Tissue Microarchitecture

- Single scattering cannot give rise to EBS.
- LEBS is generated primarily by double and higher-order scattering events in the regime where single scattering typically dominates: path  $< l_c$ .
- LEBS decreases with the increase in refractive index correlation length  $L_c$ .
- Single scattering is related to the Fourier transform of refractive index correlation function  $C(r)$  and high spatial frequencies of refractive index fluctuations (small  $L_c$ ) give rise to low frequencies in scattering characteristics ("broad" scattering features)
- LEBS peak is a non-reversing integral transform of  $C(r)$  and small  $L_c$  gives rise to high frequencies in LEBS characteristics.



Phys. Rev. E, 75, 041914, (2007)

---

---

---

---

---

---

---

---

---

---

## Lessons from Animal Studies: AOM-treated Rat and MIN-mouse Models

- LEBS was quantified by means of 4 basic parameters: enhancement coefficient, peak width, spectral slope and spectral autocorrelation decay rate.
- LEBS changes were observed far earlier than histologic markers of neoplasia.
- Optimal depth of interrogation ~100 microns (level of the mucosa up to the base of the crypt, in agreement with the location of the colonic stem cells)
- LEBS changes found in >95% of tissue sites probed by LEBS!
- Results confirmed in MIN mice

*Clinical Cancer Research, 19, 961-968 (2006)*

---

---

---

---

---

---

---

---

---

---

## Human Clinical Study Results

- 233 patients undergoing screening colonoscopy
- Mean age 56.8 ±10.7
- 47% being female
- 60 with adenomas (17 advanced adenomas)
- 9 with previous h/o adenomas but none on present colonoscopy
- 158 with no current, prior or family history of adenomas

---

---

---

---

---

---

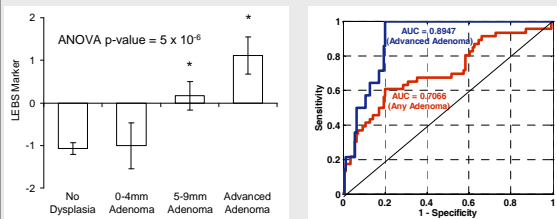
---

---

---

---

## Human Clinical Study Results



	LEBS	FOBT**	Fecal DNA**
<b>Sensitivity*</b>	100%	11%	18%
<b>Specificity*</b>	80%	95%	94%
<b>PPV</b>	42%		
<b>NPV</b>	100%		

---

---

---

---

---

---

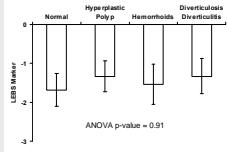
---

---

---

---

## Potential Confounding Factors Do Not Appear to Affect LEBS Diagnosis



	age	BMI
correlation coefficient	0.10	-0.038
regression p-value	0.20	0.64

	ANCOVA p-value
presence of neoplasia	0.0000
smoking history	0.0209
race	0.2235
alcohol history	0.0443
gender	0.5847
BMI	0.5857
medication history	0.9278
age	0.6526

---

---

---

---

---

---

---

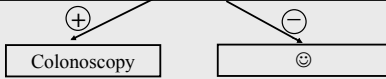---

---

---

## Colonoscopy-free Screening for Colon Cancer Using Optical Detection of the Field Effect

Annual general population screening (EIBS/LEBS) by PCP's during an annual exam without colonoscopy and preparation



- Only patients with adenomas receive colonoscopies
- Most (all) patients with adenomas are screened
- Patients are more compliant
- Better allocation of colonoscopic resource




---

---

---

---

---

---

---

---

---

---

## Conclusions

- What we call "histologically normal tissue" is not entirely normal in patients with neoplasia!
- Not only neoplastic lesions but also tissue outside the extent of neoplastic lesions is abnormal
- Biophotonics can detect field effect associated with colon carcinogenesis
- Optically-detectable markers of the field effect include increased mucosal blood supply and microarchitectural changes in mucosa
- Field effect changes are primarily limited to the mucosa (~100 um below tissue surface) – depth selectivity is key
- Alterations in the rectum are indicative of the presence of adenomas in the rest of the colon
- Potential for colon cancer screening/risk-stratification using biophotonics detection of the field effect

---

---

---

---

---

---

---

---

---

---

## Acknowledgements

### Northwestern University

Young Kim, Ph.D.  
Yang Liu, Ph.D.  
Prabhakar Pradhad, Ph.D.  
Vladimir Turzhitsky  
Andrew Gomez  
Hariharan Subramanian  
Alexander Heifitz, Ph.D.  
Alexei Kromine

### Evanston Hospital

Hemant Roy, M.D.  
Ramesh Wali, Ph.D.  
Randall Brand, M.D.  
M. Goldberg, M.D.

### Funding

National Institutes of Health  
(R01 CA109861, R01 EB003682, R01  
CA112315, R01CA118794,  
R33CA122017, R21 EB006742, U01  
CA11125)

National Science Foundation  
(CBET- 0733868, CBET-0238903)

---

---

---

---

---

---

---

---